Motion 1 – Stand alone reasons for chiropractic radiography

Subheading Question – Provide an overview of patient spinal alignment factors that enable the application of specific chiropractic spinal assessment methods, to better determine, optimise or modify either initial and/or long-term chiropractic management. Craig Moore

Introduction:

The following summary is primarily an outline of the chiropractic biophysics methodology for spine radiographic assessment and provides 81 references relating to both regional and global subluxation classification types.

Average Normal Spinal Alignment

Most health care providers accept the average values as "Normal" from a plethora of physiologic, anatomic, and biomechanical measurements (such as normal blood pressure is 120/80). Similarly, average values as "Normal" from healthy subjects for spinal alignment have been determined and published in the scientific literature. Because an average normal spinal model for each region (cervical spine, thoracic sine, and lumbar spine) was not published until recently, the Chiropractic founding fathers did not have access to any such normal values of segmental and/or global alignment. Thus they had only their intuition to guide them. However, this information is available to us at the present time.
The journal Spine first published the Chiropractic Biophysics normal spinal model in 1996. From 1996-2003, normal spinal models have been published for each region of the spine.[1 2 3 4 5 6 7] These normal spinal models are of **two types**, ***average*** [1 2 3] and ***ideal.*** [4 5 6 7] These models have been criticized by persons denying the very existence of subluxation, and have been suggested to be solely ideal or theoretical in character without clinical utility. [8 9 10 11 12] However, **average normal** spinal models have been developed and published in scientific journals. Furthermore, criticisms addressing these models have been addressed and adequately refuted. [1 2 3 13]

In these recent modeling studies of normal individuals, subject x-rays were placed on a view box where a sonic digitizer was used to touch the vertebral landmarks on the x-ray. Specifically, the x-y coordinates of the posterior aspect of the vertebral body landmarks are read and stored in a computer database. These x-y coordinates from digitization of subject films, are then used in modeling of subject spinal alignments. As a result of this 'curve fitting modeling process', pieces of circles and ellipses were found to closely approximate the alignment of the posterior body margins and thus this average normal spinal model is actually the path of the posterior longitudinal ligament (PLL) from C1-S1 (Figure 1). It is important to note that chiropractors are not the only health care clinicians that are interested in average models of the spine. Recently, orthopedic surgeons have developed an optimization approach

to model subject specific sagittal plane spinal curves; application of these models to spinal pain/deformity groups is being done as well. [14 15 16 17]

Before presenting average normal values for each motor unit (two adjacent vertebrae), we note that these average normal models have predictive validity in as much as they can discriminate between normal subjects, acute pain subjects, and chronic pain subjects in both the cervical [3] and lumbar spines. [1]

In the AP/PA view, the spine should be vertical and all end plate lines should be horizontal including occiput, C1-C7, T1-T12, L1-L5, sacral base, and a line at the tops of the femur heads (Figure 2A). These lines are the Gonstead Technique [18] wedge lines or also they are the endplate lines from which perpendiculars are drawn in the Cobb analysis, i.e., all wedge lines are parallel and all Cobb angles are 0º in the AP or PA spinal radiographic view. Another way to express this AP vertical alignment of the vertebrae is to state that all centers of mass are vertically aligned. In the cervical spine, this is equivalent to stating that the upper angle, lower angle, and CD angle on the nasium view are 90º, 90º, and 0º, respectively (See Section X Nasium X-ray view). In the thoracic and lumbar spines, this is equivalent to stating that all AP Riser-Ferguson angles (in any spinal region) are 0º (See Section X AP Thoracic, AP Lumbar, and AP Ferguson X-ray views).

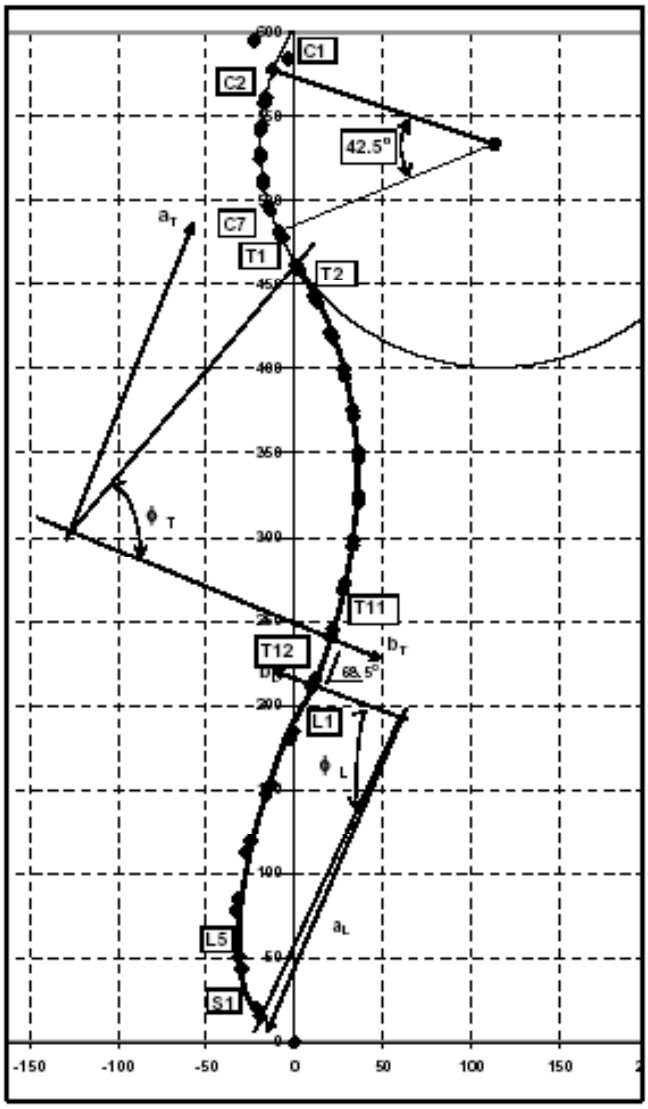

Figure 1. The 2003 Average Normal full Spine Model from C1 to S1 is the path of the PLL. The points shown for C2-S1 are the posterior vertebral body corners. The average normal full-spine model from C1 to T1 is composed of two C1 points (mid anterior arch & mid posterior margin of lateral mass) added to the C2-T1 circular model in Spine 2004. This C1-T1 model is added to the T1-T12 model by superimposing T1. Then the T12-S1 model is added, (from the Journal of Spinal Disorders). The resulting model has near perfect sagittal balance of C1-T1-T12-S1. The vertical line (VAL) for determining sagittal balance is drawn through the origin at posterior-inferior S1. Since a circle is a special ellipse with b/a = 1, this new fullspine model is composed of ellipses in the cervical, thoracic, and lumbar regions, but of different b/a ratios and different height-to length ratios. [Reprinted with permission: Harrison DE et al. Spinal Biomechanics for Clinicians, Vol I., Evanston, WY: Harrison CBP

In the sagittal view, average normal rotation angles of each motor unit (two adjacent vertebrae) can be derived from drawing lines along the posterior body margins of every vertebrae and measuring the angle of intersection of each pair (Figure 2B). In actuality, these lines represent the slopes in an Engineering analysis of structures taught in Mechanics of Materials. [19] For C1, the sacral base (S1), and the pelvic tilt, lines through these structures are often compared to a horizontal line for an angle of inclination in degrees (Figure 2B).

Segmental angles formed at adjacent vertebrae are termed Relative Rotation Angles (RRAs), while global angles (Absolute Rotation Angles are termed ARAs) in each region can be formed by comparing a superior vertebra in a sagittal region to an inferior vertebra. In this way an evaluation of the cervical lordosis (ARA C2-C7), thoracic kyphosis (ARA T1-T12 or ARA T2-T11), and lumbar lordosis (ARA L1-L5) can be measured in degrees. The reliability of these x-ray mensuration procedures will be comprehensively reviewed in Section VIII of the document.

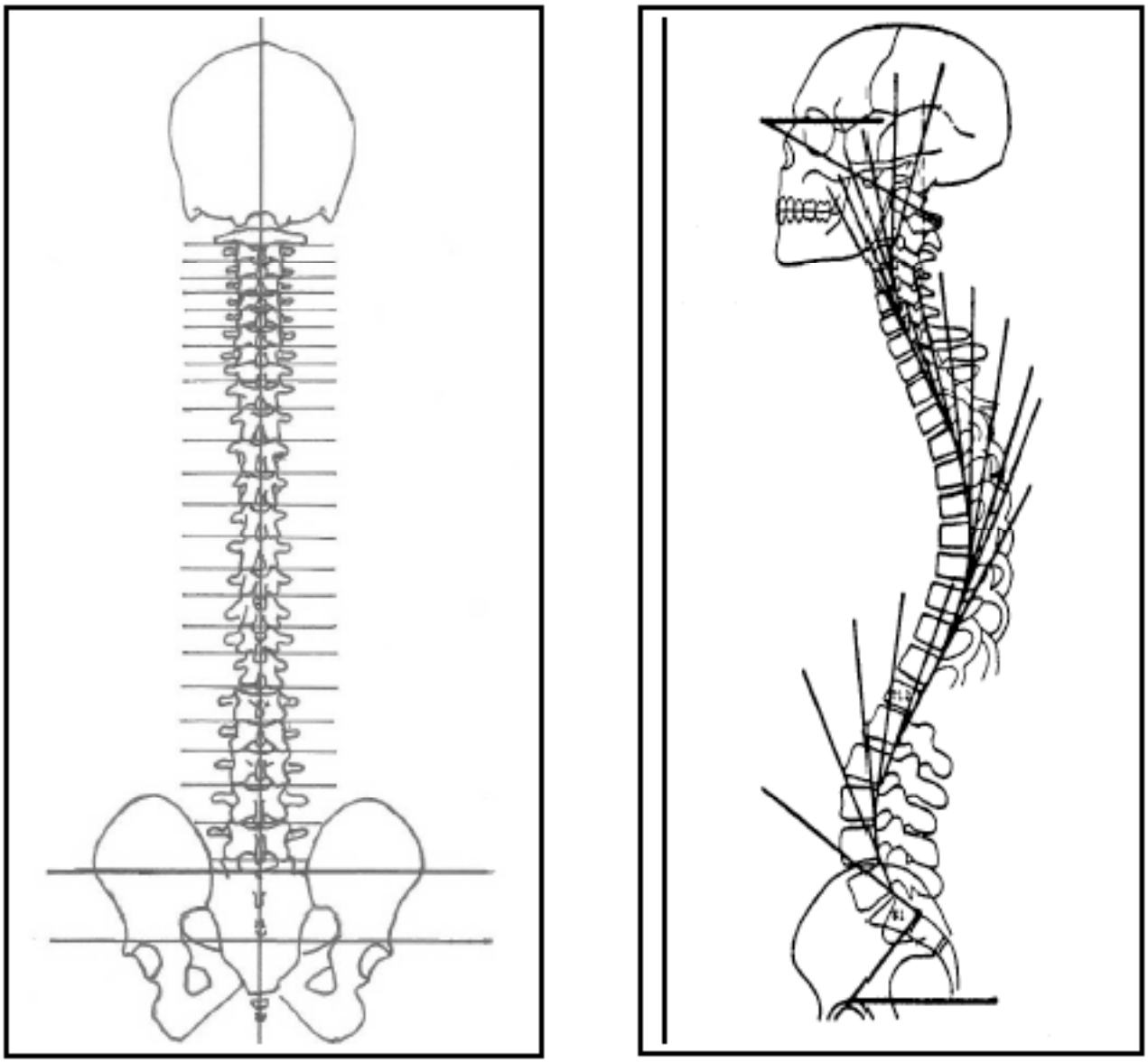

Figure 2AB. In A, the vertical alignment of the entire head, spine, and pelvis is shown. One can either express this alignment as (a) all wedge lines (end plate lines) are parallel, e.g., all Gonstead wedge angles are zero and all Cobb angles are zero, or (b) all centers of mass are vertically aligned, e.g., all Nasium upper and lower angles are zero in displacement from 90º and all Risser-Ferguson angles are zero. The Risser-Ferguson lines will meet the sacral base wedge line at 90º. In B, sagittal alignment is measured as intersecting posterior vertebral body tangents, which create segmental angles
at each pair of vertebra (RRAs) or global angles (ARAs) in each spinal region. Regional global angles are formed by choosing a superior vertebra and an inferior vertebra to intersect the posterior tangents, e.g., ARA C2-C7, ARA T3-T10, and/or ARA L1-L5. Reprinted with permission from Harrison CBP Seminars Inc., Evanston, WY

Table 1. Sagittal Cervical Average[8] and Ideal[9] Normal Values
(Reported as absolute values, since extension is –Rx)

Level	Average Value	Ideal Value
Tz C2-C7 (mm)	4 mm	0mm
Segmental Angles		
C1-Horizontal	29º	29º
C2-C3	6.4º	9.4º
C3-C4	6.9º	8.2º
C4-C5	6.8º	8.2º
C5-C6	6.6º	8.2º
C6-C7	7.8º	8.2º
Global Angles		
ARA C2-C7	34.5º	42.2º
Cobb C2-C7	26.8º	NR
Cobb C1-C7	55.1º	NR

Table 2. Sagittal Thoracic Average[7] and Ideal[10] Normal Values

Level	Average Value	Ideal Value
T2-T3	3.3°	6.8°
T3-T4	5.0°	6.3°
T4-T5	6.5°	5.9°
T5-T6	5.2°	5.5°
T6-T7	6.7°	5.2°
T7-T8	6.2°	5.0°
T8-T9	4.7°	4.8°
T9-T10	3.1°	4.7°
T10-T11	4.4°	4.7°
ARA T3-T10	37.4°	37.4°
ARA T2-T11	45.1°	49.0°

Table 3. Sagittal Lumbar Average[6] and Ideal[15] Normal Values (Reported as absolute v
since extension is –Rx)

Level	Average Value	Ideal Value
T12-L1	0°	0°
L1-L2	2.9°	5.1°
L2-L3	7.4°	6.3°
L3-L4	11.9°	9.1°
L4-L5	16.6°	18.5°
L5-S1	32.4°	33.0°
S1 to horizontal	39.2°	40.0°
ARA L1-L5	39.7°	**40.0° Rounded Up**

Since the AP alignment dictates zero degrees displacement in all end plate lines and all
lines through centers of mass, it is the average normal sagittal angles (RRAs & ARAs) that are of interest. Below, Tables (1-3) present average normal values for the RRAs and ARAs for the three spinal regions, cervical spine, thoracic spine, and lumbar spine. As expressed previously, these average values are from published average healthy subjects' spinal modeling studies. [1 2 3]

Structural Spinal Subluxation Assessment

The spinal listing is the mechanical description of the subluxation. Historically, spinal listings have been composed of letters of the alphabet to represent the direction in which a vertebra has misaligned, e.g., P = posterior, A = anterior, R = right (spinous movement in PA view), L = left (spinous movement in PA view), S = superior, and I = inferior. These directions of misalignment were observed on spinal radiographs as early as 1910. Without an education in engineering, early Chiropractic Clinicians correctly categorized all the possible movements of a motor unit (listing the top vertebra's movement relative to the vertebra immediately below) as: axial rotation, lateral bending, flexion-extension, anterolisthesis-retrolisthesis, laterolisthesis, and thin discs. Figure 3 illustrates all twelve possible vertebral misalignments in six degrees of freedom, but with listings expressed in engineering terms as rotations in degrees (Rx, Ry, Rz) and translations in millimeters (Tx, Ty, Tz).3 The origin or right-handed Cartesian coordinate
system is adopted from Panjabi et al in 1974. [20]

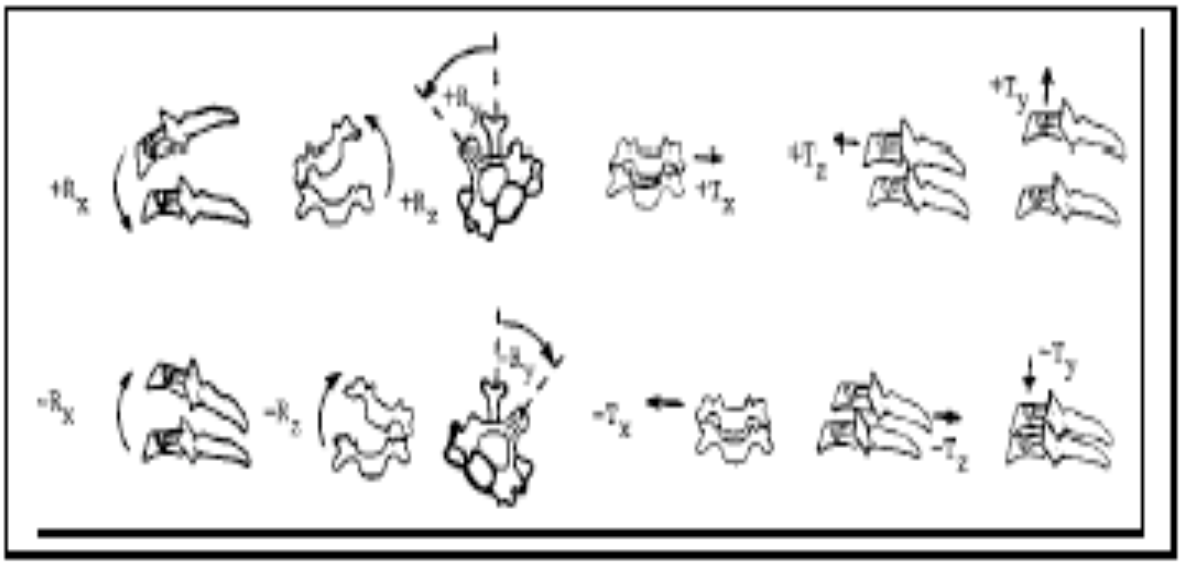

Figure 3. These are the misalignments that early Chiropractors observed on spinal x-rays after 1910. These were later described as rotations and translations in an x-y-z coordinate system in the literature in the 1970s. Using the Panjabi et al.'s coordinate system (Y vertical, X to the left, Z forward), axial rotation is ±Ry, lateral flexion is ±Rz, and flexion-extension is ±Rx, while left and right latero-listheses are ±Tx, vertical translation (thin discs and traction) are ±Ty, and antero- and retro-listheses are ±Tz. Reprinted with permission: Harrison DE et al. Spinal Biomechanics for Clinicians, Vol I., Evanston, WY: Harrison CBP Seminars, 2003

In 1972, the liberal Chiropractic Colleges' Houston Medicare Conference [21] chose 17 spinal displacements as spinal subluxations to be used by the US Federal government in defining spinal subluxation for re-imbursement of services to Chiropractors. These were/are:

A. Static intersegmental subluxations
1. Flexion malposition
2. Extension malposition
3. Lateral flexion malposition
4. Rotational malposition
5. Anterolisthesis
6. Retrolisthesis
7. Altered interosseous spacing (decrease/increase)
8. Osseous foraminal encroachment

B. Kinetic intersegmental subluxations
9. Hypomobility (fixation)
10. Hypermobility
11. Aberrant motion.

C. Sectional subluxations
12. Scoliosis and/or alteration of curves secondary to musculature imbalance
13. Scoliosis and/or alteration of curves secondary to structural asymmetries
14. Decompensation of adaptational curvatures
15. Abnormalities of motion.

D. Paravertebral subluxations
16. Costovertebral and costotransverse disrelationships
17. Sacroiliac subluxations

It is important to note that using the average normal spinal model in Figure 1 and Tables 1-3, these displacements (listings) can be measured in degrees of rotation and millimeters of translation. Additionally, using the methods suggested in Figure 2A (Gonstead, Cobb, Risser-Ferguson, upper and lower angles on the nasium), it is possible to measure "Sectional Subluxations" (regional subluxations) in degrees of displacement from normal.
However, these "Sectional Subluxations" are more clearly described in engineering terms as buckling, i.e., snap through buckling = sagittal buckling in harmonics or eigenvalues and their eigensolutions (types of "S"-curves), Elastic buckling of a column, or Euler buckling of a column. [22 23 24 25]

Subluxation Types

Using the reference frame from Panjabi et al, [20] there are four types of observed postural and spinal segmental subluxations (displacements), which have been adequately described in mechanical engineering terms and verified by biomechanical investigations. In 1998, Harrison et al 5 presented a detailed review of the literature of these four types. In the current document, we add to the four types of subluxation discussed by Harrison et al [26] and present these as types of structural/mechanical displacements of the spine ("bone out of place"):

1. Segmental subluxations: These are the segmental displacements from C1-S1 measured from the vertebra above relative to an origin located in the vertebra immediately below. These vertebral spinal subluxations are listed in terms of Rx, Ry, Rz, Tx, Ty, Tz), [18 27 28 29 30] (**See Figure 3**). Triano [27] discussed these segmental displacements in terms of a buckling phenomenon but only discussed their post-buckled behavior (kinematic alterations) while neglecting the fact that these are associated with static displacements described as their respective post-buckled modes. The only valid way to identify these segmental displacements (post-buckled segmental modes or kinematic alterations) is by radiographic means. [18 28 29 30]

2. Postural main motion and coupled motion: Postural displacements found in neutral resting stance are completely described as rotations and translation displacements of the head, thoracic cage, and pelvis. The majority of these displacements are concomitantly associated with spinal coupling/displacement patterns. 26 [31 32 33 34 35] Each postural displacement has a unique spinal displacement pattern, with which it is normally associated.

3. Snap-through buckling in the sagittal plane: The alterations in the regional sagital curves of cervical or lumbar lordosis to kyphosis and "S"-curves and, to some extent, changes in thoracic kyphosis to hypo-or hyper-kyphosis have been found to be consistent with the engineering Snap-through type of buckling. [36 37 38 39 40 41 42 43 44 45 46 47 48]
According to Nightingale et al [39], referring to Chen and Lui [23], "*In a column with a fixed base, buckling is evidenced by an abrupt decrease in measured compressive load with increasing deflection and moment. Snap through buckling is characterized by a visible and rapid transition from one equilibrium configuration to another*".
Snap through buckling can occur in 1 of 3 ways: a) an abrupt impact load applied to the head, ribcage, or pelvis, b) an overload event such as bending forward and lifting a very heavy object, or 3) an inertial loading event causing rapid acceleration and inertial loads to the spinal segments such as a rear end motor vehicle accident. [36 37 38 39 40 41 42 43 44 45 46 47 48] Increased complexity of the snap-through buckling is delineated in terms of the shape of the curves. An S-shape in any region (cervical, thoracic, lumbar) is the 1st order buckled mode, flexion-extension-flexion in any region is the 2nd order buckled mode, etc. In experiments, 2nd order and higher buckled modes are caused by dynamic loading and are associated with large

increases in potential energy whereas 1st order buckled modes have been produced under static and quasi-static loading experiments. **See Figure 5**.

4. Euler buckling in AP/PA view: This type of structural displacement is generally where the structures of the lower most segments in a spinal region experience some failure, e.g., axial rotation and/or lateral flexion of L4 and L5. [26 49 50 51] These displacements are generally localized to the distal spinal regions of the cervical, thoraco-lumbar, and lumbo-pelvic and are generally associated with sub-catastrophic (non-complete tears) and sometimes catastrophic (macro) tears in the surrounding ligaments. These occur under similar loading circumstances as Snap through buckling detailed above. **See Figure 6**.

5. Scoliosis: Recently, the pathomechanics and perhaps the eitiology of the non-neurogenic forms of scoliosis have been described by a 'slow-loading' buckling mechanism. [35 52] There are multiple different types, locations and complexities of scoliosis.

6. Static or dynamic segmental instability: These are the segmental displacements depicted in Figure 3 but are at the limit of or past the limit for range of motion of the functional spinal unit. These are associated with significant ligamentous trauma. This information is detailed in Section X of this document under dynamic imaging and flexion/extension radiography. [53 54 55 56 57 58 59 60 61]

These 6 types of subluxation are mechanical descriptions for the allowable spinal displacements that can occur. Using the average normal spinal model, inside normal upright stance, that we precisely defined in Figure 1, these 6 types of displacements can be quantified. It is an important feature that each one of the structural subluxations (except for instability, number 6 above) is a displacement that occurs within the allowable range of motion of the functional spinal motion segment. Thus, these 5 subluxations are static and dynamic mechanical displacements that are sustained within the range of joint motion. Also, we note that the above 6 types of structural subluxation are listed in increasing complexity of the displacement until we reach complete ligamentous failure or instability (number 6).

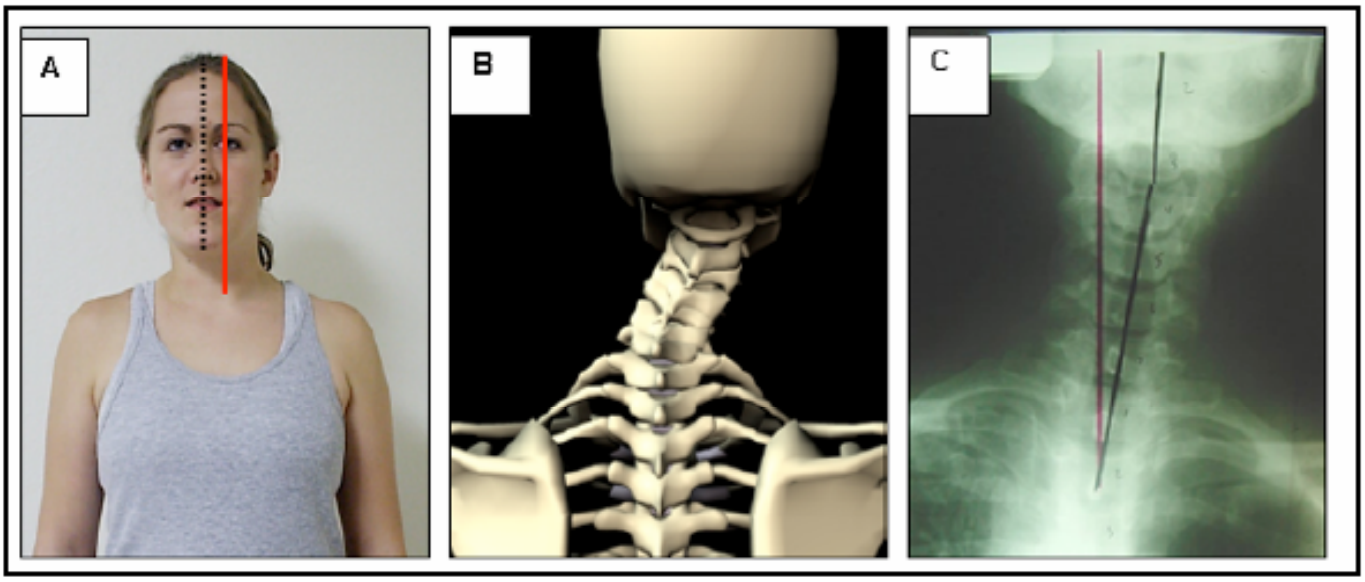

Figure 4. Postural Main Motion and Coupled motion. In A, the posture of right head translation is shown. In B, the skeletal animation from the posterior to anterior view is shown depicting the opposite lateral bending coupling motions in the mid-low cervical spine versus the mid-upper cervical spine. In C, a patient radiograph is shown with the coupling patterns for right head translation. Reprinted with permission from Harrison CBP Seminars Inc., Evanston, WY.

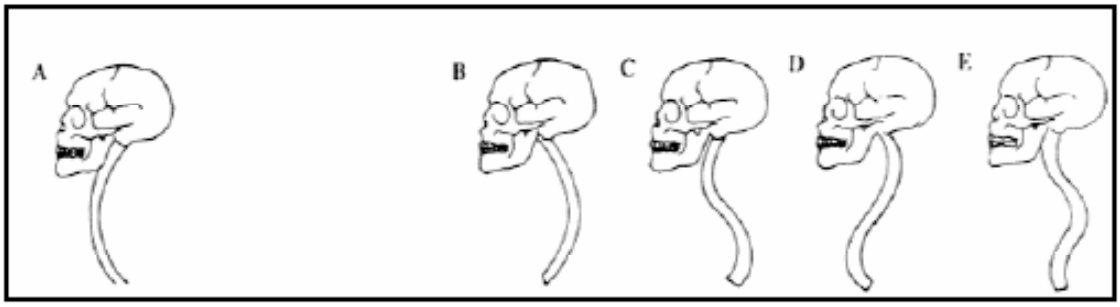

Figure 5. Snap Through Buckling. In A, the neutral lordosis is shown. The buckled modes (B-E) are caused by impact, overload, or inertial loading events. Increasing complexity is referred to as 1st order buckled modes (C and D), 2nd order buckled modes (E), etc…. The allowable shapes can be correlated to eigenvalues in solutions of nonlinear partial differential equations used to model structures.[45,46] Reprinted with permission from Harrison CBP Seminars Inc., Evanston, WY.

Anatomic/Anomaly Variants Affecting Spinal Geometry

An important topic when discussing our average spinal models' application to the human population is a consideration of anatomical variations in a given persons spinal anatomy. There are several known anatomical variants of human spinal anatomy that affect spinal alignment/geometry, however, there are several variants that do not. Significant progress has been made in understanding the correlations between a variety of anatomical variants and spine geometric alterations; Chiropractic clinicians and researchers have played a significant role in this area of investigation.

We continue to make progress understanding the context and accommodating for these variants. [12 62 63 64 65 66] For example, in a recent 2005 Chiropractic text, Peterson and Hsu, [12] claim that chiropractic roentgenometric measurement of spinal subluxation is "*...controversial within the profession, particularly because the impact of natural and normal asymmetries with the body on these measurements is not known.*" In support of their statement, the opinion article by Haas et al [62] and the investigation by Peterson et al [63] are offered. Despite claims, there is no referenced evidence to support the view that 'natural asymmetry' of the spinous processes altering spinal geometry in the AP view. In contrast, Farfan [67] found that when the spinous process is asymmetrical, the entire vertebral architecture will change and keep the lamina junction in line with the structural center of the vertebral body. This means the center of mass of the vertebral body will remain approximately the same. Farfan [67] states "*It would appear that in the development of the vertebra, asymmetrical body growth is compensated for by asymmetric growth of the neural arch*".

The second investigation offered by Peterson and Hsu [12] to criticize the chiropractic clinicians' use of spinal radiography, is the study by Peterson et al. [63] With a small sample size and no segmental analysis of cervical lordosis, Petersen et al [63] claimed that alterations in the angle of the facet surfaces in the sagittal plane caused a reduction in the magnitude of the cervical lordosis. The claim that facet architecture/angles influence the cervical curve can be traced to a single 1977 self-published text by MacRae. [64] with only Class V evidence given. Winterstein [65] claimed that "*short pedicles and vertically facing articular facets predispose to a cervical hypolordosis or kyphosis.*" Winterstein offered no references for such statement. Peterson et al were challenged in a letter by Harrison et al [68]

Harrison et al [69] performed a much needed investigation using 252 subjects, where the correlation between articular pillar height, facet surface sagittal plane angles, and the shape of the dens and the segmental and total cervical spine curvature was determined. Harrison et al concluded,
"In contrast to chiropractic radiology paradigms in the literature, we found no

statistical correlation with hyperplasia of the cervical facets (superior and inferior facet surfaces that diverge to the posterior) and any segmental or global angle of cervical lordosis. Additionally, there is no correlation with the vertical heights of the cervical facets and any segmental or global angle of cervical lordosis."

There are spinal anatomical variants that do affect the geometry of the spine and these include the following:

1. Sagittal plane wedge angles of the vertebral bodies, [70] [71] [72]
2. Coronal plane wedge angles of the vertebral bodies (hemi-vertebra), [73]
3. Anomalies of the skull condyles, 66 [74] [75] [76] [77] [78]
4. Transitional vertebra at L5-S1, [79] [80]
5. Congenital and surgical blocked vertebra, [81] and
6. Pelvic/sacral morphology. [14] [15] [16] [17]

Chiropractic pioneers (clinicians and researchers) and other health care physicians are on the forefront of investigating spinal anomalies, learning to identify them via radiographic means, and developing treatment strategies that account for the anatomical variances. [72] [74] [75] [76] [79]

References:

1 Harrison DD, Cailliet R, Janik TJ, Troyanovich SJ, Harrison DE, Holland B. Elliptical Modeling of the Sagittal Lumbar Lordosis and Segmental Rotation Angles as a Method to Discriminate Between Normal and Low Back Pain Subjects. J Spinal Disord 1998; 11(5): 430-439.

2 Harrison DE, Janik TJ, Harrison DD, Cailliet R, Harmon S. Can the Thoracic Kyphosis be Modeled with a Simple Geometric Shape? The Results of Circular and Elliptical Modeling in 80 Asymptomatic Subjects. J Spinal Disord Tech 2002; 15(3): 213-220

3 Harrison DD, Harrison DE, Janik TJ, Cailliet R, Haas JW, Ferrantelli J, Holland B. Modeling of the Sagittal Cervical Spine as a Method to Discriminate Hypo-Lordosis: Results of Elliptical and Circular Modeling in 72 Asymptomatic Subjects, 52 Acute Neck Pain Subjects, and 70 Chronic Neck Pain Subjects. Spine 2004; 29(22):2485-2492

4 Harrison DD, Janik TJ, Troyanovich SJ, Holland B. Comparisons of Lordotic Cervical Spine Curvatures to a Theoretical Ideal Model of the Static Sagittal Cervical Spine. Spine 1996; 21(6):667-675

5 Harrison DD, Harrison DE, Janik TJ, Cailliet R, Haas JW. Do Alterations in Vertebral and Disc Dimensions Affect an Elliptical Model of the Thoracic Kyphosis? Spine 2003; 28(5): 463-469

6 Harrison DD, Janik TJ, Troyanovich SJ, Harrison DE, Colloca CJ. Evaluations of the Assumptions Used to Derive an Ideal Normal Cervical Spine Model. J Manipulative Physiol Ther 1997;20(4): 246-256

7 Janik TJ, Harrison DD, Cailliet R, Troyanovich SJ, Harrison DE. Can the Sagittal Lumbar Curvature be Closely Approximated by an Ellipse? J Orthop Res 1998; 16(6):766-70

8 Oakley PA. Its Paul's Opinion: Triano should stop bad mouthing Harrison's work and accept it as clinical evidence for the CCPGG Guidelines. American Journal of Clinical Chiropractic 2005;14(4): 3

9 Oakley PA. It's Paul's Opinion: CBP Researchers at 2004 ACC/RAC. American Journal of Clinical Chiropractic 2004; 13(2): 3

10 Triano JJ. Statements during a talk to the Faculty of Cleveland Chiropractic College Kansas City. Kansas City, MO, August 2004

11 Nelson CF, Lawrence D, Triano D, Bronfort G, Perle SM, Metz D, Hegetschweiler K, LaBrot T. Chiropractic as spine care: a model for the profession. Chiropractic & Osteopathy 2005;13:9

12 Peterson C and Hsu W. Indications for and use of x-rays. Chapter 33. In: Haldeman S., editor, Modern Developments in Chiropractic, 3rd edition. New York: McGraw-Hill Companies, Inc.,2005; pp. 661-681

13 Harrison DE, Harrison DD, Troyanovich SJ. A Normal Spinal Position, Its Time to Accept the Evidence. J Manipulative Physiol Ther 2000; 23: 623-644

14 Berthonnaud E, et al. Analysis of the sagittal balance of the spine and pelvis using shape and orientation parameters. J Spinal Disorders & Techniques 2005;18(1):40-47

15 Roussouly P, et al. Classification of the normal variation in the sagittal alignment of the human lumbar spine and pelvis in the standing position. Spine 2005;30(3):346-353

16 Vialle R, et al. Radiographic analysis of the sagittal alignment and balance of the spine in asymptomatic subjects. JBJS Am 2005;87:260-267

17 Vaz G, et al. Sagittal morphology and equilibrium of pelvis and spine. Eur Spine J 2002;11:80- 87

18 Rowe SH, Ray SG, Jakubowski AM, Picardi RJ. Plain Film Radiography in Chiropractic. Chapter 5. In: Plaugher, ed. Textbook of Clinical Chiropractic. A Specific Biomechanical Approach. Williams & Wilkins, Baltimore. 1993; pages 112-149

19 Beer FP, Johnston ER, Jr. Mechanics of Materials. 2nd Edition. New York: McGraw-Hill, Inc., 1992

20 Panjabi MM, White AA, Brand RA. A note on defining body parts configurations. J Biomech 1974;7:385-390

21 Houston Conference. Radiological Manifestations of Spinal Subluxations. Uniformity in Medicare Reporting, November 1972

22 Gilmore R. Catastrophe theory for scientists and engineers. New York, Dover Publications, 1981

23 Chen WF, Lui EM. Structural Instability: Theory and Implementation. Elsevier, New York; 1987, pgs 4-10

24 Pilkey WD, Wunderlich W. Mechanics of structures: variational and computational methods. Boca Raton: CRC Press;1994. pages 617-635

25 Como M, Grimaldi A. Theory of stability of continuous elastic structures. Boca Raton: CRC Press;1995. pages 6-9, 188-210

26 Harrison DE, Harrison DD, Troyanovich SJ. Three-Dimensional Spinal Coupling Mechanics. Part II: Implications for Chiropractic Theories and Practice. J Manipulative Physiol Ther 1998; 21(3): 177-86

27 Triano J. The theoretical basis for spinal manipulation. Chapter 19. In: Haldeman S., editor, Modern Developments in Chiropractic, 3rd edition. New York: McGraw-Hill Companies, Inc., 2005;pgs 361-381

28 Cholewicki J, McGill SM. Lumbar posterior ligament involvement during extremely heavy lifts estimated from fluoroscopic measurements. J Biomech 1992;25:17-28

29 McGill SM. The biomechanics of low back injury: Implications on current practice in industry and the clinic. J Biomech 1997;30:465-475. Diagnostic Imaging 71

30 Owens EF, Eriksen K. Upper cervical post x-ray reduction and its relationship to symptomatic improvement and spinal stability. CRJ: 1997(4:2):10-17

31 Harrison DE, Cailliet R, Harrison DD, Janik TJ, Troyanovich SJ, Coleman RR. Lumbar Coupling During Lateral Translations of the Thoracic Cage Relative to a Fixed Pelvis. Clin Biomech 1999: 14(10):704-709

32 Harrison DE, Cailliet R, Harrison DD, Troyanovich SJ, Janik TJ. Cervical Coupling on AP Radiographs During Lateral Translations of the Head Creates an S-Configuration. Clin Biomech 2000; 15(6): 436-440

33 Harrison DE, Cailliet R, Harrison DD, Janik TJ. How Do Anterior/Posterior Translations of the Thoracic Cage Affect the Sagittal Lumbar Spine, Pelvic Tilt, and Thoracic Kyphosis? Eur Spine J 2002; 11(3): 287-293

34 Ordway NR, Seymour R, Donelson RG et al. Cervical sagittal range-of-motion analysis using three methods. cervical range-of-motion device, 3space, and radiograph. Spine 1997;22:501-508

35 Azegami, H, Murachi S, Kitoh J, Ishida Y, Kawakami N, Makino M. Etiology of idiopathic scoliosis. Clin Orthopedics Rel Res 1998;357:229-236

36 Yoganandan N, Pintar FA, Arnold P, Reinartz J, Cusick JF, Maiman DJ, Sances A. Continuous motion analysis of the head-neck complex under impact. J Spinal Disorders 1994;7:420-428

37 Oktenglu T, Ozer F, Ferrara LA, Andalkar N, Sarioglu AC, Benzel EC. J Neurosurg (Spine 1) 2001;94:108-114

38 Nightingale RW, Camacho DL, Armstrong, Robinette JJ, Myers BS. Inertial properties and loading rates affect buckling modes and injury mechanisms in the cervical spine. J Biomechanics 2000;33:191-197

39 Nightingale RW, McElhaney JH, Richardson WJ, Myers BS. Dynamic responses of the head and cervical spine axial impact loading. J Biomechanics 1996;29:307-318

40 Nightingale RW, McElhaney JH, Richardson WJ, Best TM, Myers BS. Experimental impact injury to the cervical spine: Relating motion of the head and the mechanism of injury. J Bone and Joint Surgery AM 1996;78-A:412-421

41 Fukushima M, Kaneoka K, Ono K, Sakane M, Ujihashi S, Ochiai N. Neck injury mechanisms during direct face impact. Spine 2006;31:903-908

42 Garcia T, Ravani B. A biomechanical evaluation of whiplash using a multi-body dynamic model. Transactions of ASME 2003;125:254-265

43 Panjabi MM, Pearson AM, Ito S, Ivancic PC, Wang JL. Cervical spine curvature during simulated whiplash. Clin Biom 2004;19:1-9

44 Stemper BD, Yoganandan N, Pintar FA. Effects of abnormal posture on capsular ligament elongations in a computational model subjected to whiplash loading. J Biomechanics 2005; 38:1313-1323

45 Stemper BD, Yoganandan N, Pintar FA. Effect of head restraint backset on head-neck kinematics in whiplash. Accident Analysis & Prevention 2006;38:317-323

46 Matsunaga, S, Sakou T, Sunahara N, Oonishi T, Maeda S, Nakanisi K. Biomechanical analysis of buckling alignment of the cervical spine. Spine 1997;22:765-771

47 Matsunaga S, Sakou T, Nagayama T, Nakanisi K. A new biomechanical analysis of the degenerative lumbar spine. In: Takahashi HE, editor. Spinal disorders in growth and ageing. Tokyo:Springer-Verlag,1995;p.175-182

48 Matsunaga S, Sakou T, Taketomi I, Ijiri K. Comparisons of operative results of lumbar disc herniations in manual laborers and athletes. Spine 1993;18:2222-6

49 Goel VK, Weinstein JN, Patwardhan AG. Biomechanics of intact ligamentous spine. In: Goel VK, Weinstein JN, editors. Biomechanics of the Spine: Clinical and surgical Perspective. Boca Raton: CRC Press;1990; pg 135

50 Crisco JJ, Panjabi MM. Euler stability of the human ligamentous lumbar spine. Part 1: theory. Clin Biomech 1992;7:19-26

51 Crisco JJ, Panjabi MM, Yamamoto I, Oxland TR. Euler stability of the human ligamentous lumbar spine. Part II: experiment. Clin Biomech 1992;7:27-32

52 Weiler PJ, Buckling analysis of spinal implant devices used for the surgical treatment of scoliosis. MASc Thesis, Department of Civil Engineering. Ontario (Canada): University of Waterloo;1983

53 Pope MH, Panjabi MM. Biomechanical definitions of spinal instability. Spine 1985;10:255-266

54 Farfan HF. The pathological anatomy of degenerative spondylolisthesis. Spine 1980;5:412-418

55 Paris SV. Physical signs of instability. Spine 1985;10:277-279

56 Panjabi MM, Abumi K, Duranceau J, Oxland T. Spinal stability and intersegmental muscle forces, a biomechanical model. Spine 1989;14:194-199

57 Dupuis PR, Cassidy JD, Kirkaldy-Willis WH. Radiological diagnosis of degenerative lumbar spinal instability. Spine 1985;10:262-276

58 Friberg O. Lumbar instability: a dynamic approach by traction-compression radiography. Spine 1987;12:117-129

59 Dvorak J, Panjabi MM, Gerber M, Wichmann W. CT-Functional diagnostics of the rotatory instability of the upper cervical spine. Part 1: an experimental study on healthy cadavers. Spine 1987;12:197-205

60 Dvorak J, Hayek J, Zehnder R. CT-functional diagnostics of the rotatory instability of the upper cervical spine. Part 2: an evaluation on healthy adults and patients with suspected instability. Spine 1987;12:726-731

61 Fazl M, LaFebvre J, Willinsky RA et al. Posttraumatic ligamentous disruption of the cervical spine, an easily overlooked diagnosis: presentation of three cases. Neurosurgery 1990;26:674-8

62 Haas M, Taylor JA, Gillette RG. The routine use of radiographic spinal displacement analysis: a dissent. J Manipulative Physiol Ther 1999;22(4):254-9

63 Peterson CK, Kirk RJ, Isdahl M, Humphrey BK. 1999. Prevalence of hyperplastic articular pillars in the cervical spine and relationship with cervical lordosis. J Manipulative Physiol Ther 22:390-394

64 MacRae JE. 1977. Roentgenometrics. 1st edition. Toronto, Canada: JE MacCrae

65 Winterstein JF. 2002. Letter. J Manipulative Physiol Ther 25:283

66 Morrison R, Conley R, Palmeri C, Rustici C. Asymmetry of the occipital condyle facet surfaces utilizing magnetic resonance images. Proceedings of the World Federation of Chiropractic 7th Biennial Congress; Orlando, FL., May 2003:288

67 Farfan HP. Mechanical Disorders of the Low Back. Philadelphia: Lea & Febifer, 1973:34-35

68 Harrison DD, Harrison DE, Troyanovich SJ, Harrison SO. 2000. Letter. J Manipulative Physiol Ther 23(5): 366-368

69 Harrison DE, Haas JW, Harrison DD, Janik TJ, Holland B. Do Sagittal Plane Anatomical Variations (Angulation) of the Cervical Facets and C2 Odontoid Affect the Geometrical Configuration of the Cervical Lordosis? Results from Digitizing Lateral Cervical Radiographs in 252 neck pain subjects. Clin Anat 2005; 18:104-111

70 Manns et al. Clinical Radiology 1996:51:258-262

71 Cheng XG, Sun Y, Boonen S, Nicholson PH, Brys P, Dequeker J, Felsenberg D. Measurements of vertebral shape by radiographic morphometry: sex differences and relationships with vertebral level and lumbar lordosis. Skeletal Radiol 1998;27(7):380-384

72 Harrison DE, Harrison DD, Haas JW. CBP: Structural Rehabilitation of the Cervical Spine. Harrison Chiropractic Biophysics Seminars, Inc. 2002; Chapter 3, pg 61-62

73 Bollini G, Docquier PL, Viehweger E, Launay F, Jouve JL. Lumbosacral hemivertebrae resection by combined approach. Medium-and long-term follow-up. Spine 2006; 31:1232-1239

74 . Blair R. Blair Procedures. ICA Review of Chiropractic, 1968

75 Blair Research Society in Lubbock, Texas

76 Harrison DD. Chiropractic: The Physics of Spinal Correction with CBP Technique.

Evanston, WY: Harrison CBP Seminars, 1986, 1992, 1994, 1998: Chapter 3

77 Cave JE. On the occipito-atlanto-axial articulations. J Anatomy 1934;68:416-423

78 Allen W. On the varieties of the atlas in the human subject and the homologies of its transverse Process. J Anatomy 1879;14:18-28

79 Juhl JH, Ippolito Cremin TM, Russell G. Prevalence of frontal plane pelvic postural asymmetry--part 1. J Am Osteopath Assoc. 2004 Oct;104(10):411-21

80 Beck RW, Holt KR, Fox MA, Hurtgen-Grace KL. Radiographic Anomalies That May Alter Chiropractic Intervention Strategies Found in a New Zealand Population. J Manipulative and Physiol Ther 2004;27(9):554-559

81 Harrison DE, Harrison DD, Oakley P, Haas JW. The Lumbar Lordosis. Ch 4. In: CBP: Structural Rehabilitation of the Lumbar Spine. Harrison Chiropractic Biophysics Seminars, Inc. 2006